Lec Oral pathology Dr. Afrah Adnan

Biopsy

Oral and maxillofacial pathology: is the specialty of dentistry and the discipline of pathology that addresses the identification, nature and management of diseases affecting the oral and maxillofacial regions.

Surgical Pathology: is that specialty of pathology which deals with the diagnosis of diseases by microscopical examination of tissues taking by a surgeon ((Biopsy)).

The pathologist is taken a careful history and clinical examination with other investigation and another opinion (consultation and referral) may be necessary to reach a firm diagnosis.

Biopsy may be defined as removal of tissue from a living organism for histopathological examination.

the use of biopsy is not restricted to the diagnosis of the tumors, but is invaluable in determining the nature of any unusual lesion, However not all lesions present a specific microscopic appearance and for this reason a definitive diagnosis cannot always be made. The need for special techniques in surgical pathology is sometimes needed to reach a final diagnosis.

Types of biopsy according to the size of tissue that to be biopsied:-

1- Incisional biopsies, only a portion of the lesion are sampled, and therefore the procedure is strictly of a diagnostic nature.

2- Excisional biopsy, the entire lesion is removed, usually with a rim of normal tissue, and therefore the procedure serves both a diagnostic and a therapeutic function.

Types of biopsy according to the instruments used to obtain them:-

1-Cautery: this technique is least suitable for microscopic interpretation because this instrument chars and distorts tissues.

2-Cone biopsy: it removes a cylindrical or cone shaped piece of tissue, it is performed to diagnose cervical cancer following a pap smear.

Colposcopy (examination of the cervix under illuminated magnification), and a punch biopsy.

3-Core needle biopsy: it is performed by inserting a small hollow needle through the skin and into the organ or abnormality to be investigated. The needle is then advanced within the cell layers to remove a sample or core. Needle biopsy is also a type of percutaneous (through the skin) biopsy. The needle may be designed with a cutting tip to help remove the sample of tissue. Core biopsy is often performed with the use of spring loaded gun to help remove the tissue sample.

4-Vacuum Assisted Biopsy: Core biopsy is sometimes suction assisted with a vacuum device. This method enables to removal of multiple samples with only one needle insertion. Vacuum assisted core biopsy is being used more and more in breast biopsy procedures

5-Endoscopic Biopsy: Endoscopic biopsy is a very common type of biopsy that is done through an endoscope (a fiber optic cable for viewing inside the body) which is inserted into the body along with sampling instruments.

6-Punch Biopsy: Punch biopsy is typically used by dermatologists to sample skin rashes, moles and other small masses. After a local anesthetic is injected.

7-Surface Biopsy: Surface biopsy involves sampling or scraping the surface of a sore or tumor to remove cells for pathologic testing. Surface biopsy is often performed by dermatologists to remove a small piece of skin to test for carcinoma (cancerous tissue).

Indications for Biopsy

- Any lesion that persist for more than 2 weeks with no apparent etiologic basis.
- Any inflammatory lesion that does not respond to local treatment after 10-14 days.
- Persistent hyperkeratotic changes in surface tissue.
- Any persistent tumescence, either visible or palpable beneath relatively normal tissue.
- Lesion that interfere with local function.
- Bone lesions not specifically identified by clinical and radiographic findings.
- Any lesion that has the characteristics of malignancy.
- Erythroplasia-lesion is totally red or has speckled red appearance.
- Ulceration-lesion is ulcerated or present as an ulcer persisted for more than 2 weeks.
- Growth rate-lesion exhibits rapid growth.
- Bleeding-lesion bleeds on gentle manipulation.
- Induration-lesion and surrounding tissue is firm to the touch.
- Fixation-lesion feels attached to adjacent structures.

Dr. Afrah Adnan Alselaimi

Contraindications for Biopsy

- Acute inflammatory conditions such as cellulitis
- Normal anatomical variations such as linea alba
- Patients with bleeding disorders
- Vascular lesions such as haemangioma

- Patients who are on anticoagulant therapy

Characteristics of lesions that raise the suspicion of malignancy:

- **Erythroplasia:** lesion has red or speckled red appearance.
- **Ulceration:** lesion is ulcerated or present as an ulcer.
- **Duration:** lesion persisted more than 2 weeks.
- **Growth rate:** lesion exhibits rapid growth.
- **Bleeding:** lesion bleeds on gentle manipulation.
- **Induration:** lesion and surrounding tissues are firm to touch
- **Fixation:** lesion feels attached to adjacent structures.

Excisional Biopsy

Excisional biopsy is the total removal of the pathological tissue along with margin of normal tissue. It is indicated when the size of the pathological tissue is less than 2 cm and the surgical procedure can be performed at the dental clinic.

The procedure: Administrations of local anesthesia at the periphery of the lesion then two elliptical incisions are made on normal tissue surrounding the lesions that are joined at an acute angle. The lesion is then removed, the mucosa is undermined using blunt scissors, the wound margins are re-approximated and suturing is performed, and healing is achieved by primary intention. If the lesion is located at the gingiva or palate, suturing is not possible. In such a case a surgical dressing is applied and the wound heals by secondary intention.

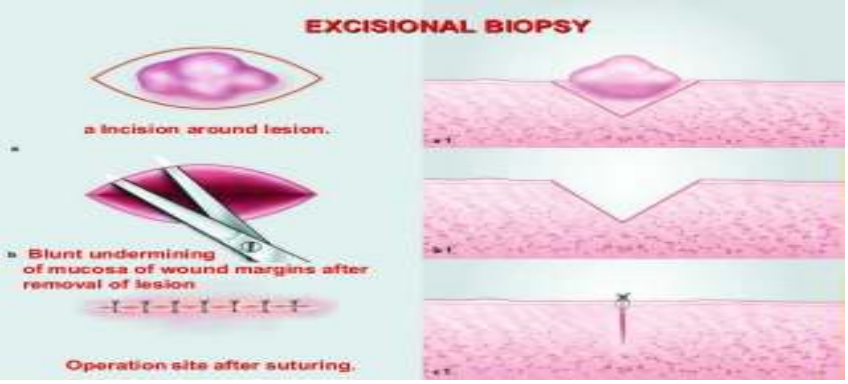

Incisional Biopsy or Wedge Biopsy

Incisional biopsy is the partial removal of the pathological tissue along with margin of normal tissue. It is indicated when the size of the pathological tissue is more than 2 cm.

The procedure: After local anesthesia, a wedge-shaped portion of the most representative part of the lesion is removed, usually from the periphery of the lesion, extending into normal tissue then sutured. In general necrotic tissues should be avoided and a narrow deep specimen is better than a broad shallow one.

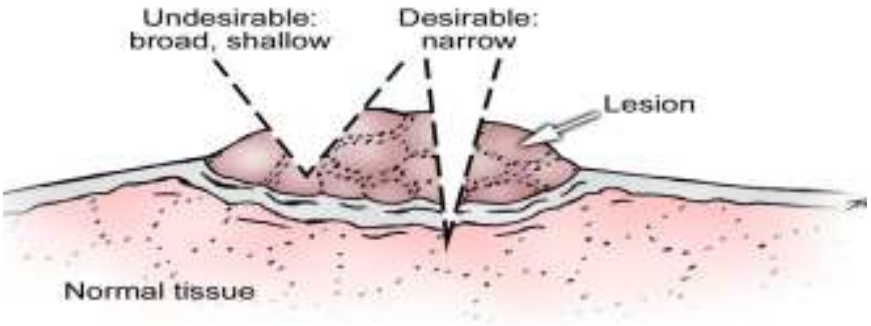

Diagnostic cytology:

It generally refers to the study of cells found in living things. Diagnostic cytology is the process of studying cells to identify diseases. Procedures to obtain cell samples to perform cytological evaluations are varied, but usually involve taking either a sample of body fluids or a scraping of cells

from body tissue. Diagnostic cytology may be used to help identify various types of cancer and certain infections.

- Cytology is not a substitute but an adjunct to the surgical biopsy.
- It is quick, simple, painless and bloodless procedure.
- It helps as a check against false – negative biopsies.
- It is helpful in follow-up and detection of recurrent carcinoma in previously treated cases.
- It is valuable for screening lesions that grossly biopsy is not warranted.

Brush Biopsy

It is a diagnostic technique of obtained full transepithelial tissue, which can be taken in the dental office. In comparison to Exfoliative cytology, brush biopsy has an upper hand because the technique is take the full thickness of epithelia to reach the connective tissue.

Advantages of brush biopsy

• Reduced chair side time
• Simple procedure which is easy to master
• Quick results

Fine Needle Aspiration Biopsy

Aspiration biopsy is very inexpensive, quick and easily performed technique. The complete trans-tumor sample is composed of cells, tissue, or fluid and is useful in diagnosis of fluctuant lesions, deep-seated submucosal lesions and metastasis in enlarged cervical lymph nodes.

The procedure: by using a trocar needle or fine needle (21-23gauge) adapted to plastic disposable syringe. The needle is inserted into the fluctuant swelling or the enlarged cervical lymph nodes and moved up and down. Once the cells, tissue, or fluid is aspirated, the needle is withdrawn from the swelling and sent for either protein estimation or cytological

examination. The aspirated material is smeared on a glass slide and immersed in Hoffman solution (95% ethyl alcohol solution and 5% ether solution) in equal parts or it is fixed with hair spray. Cytological examination is then performed.

Advantages: Painless, Diagnosis available within 1 hour, Inexpensive procedure, Complications is very rare.

Exfoliative Cytology

It is collected and examined cells shed from body surfaces, such as the inside of the mouth. This technique is useful only for the examination of surface cells but it has not been a very useful for diagnosis of oral cancer because a greater proportion of malignant diagnostic cells are below the surface (most at the basement membrane level)

Laser Biopsy

Lasers can be effectively used for incisional and excisional biopsies. Lasers have a advantages over the conventional scalpel because of the following reasons:

1. Patient acceptance
2. There is little or no bleeding
3. Excellent visibility
4. Reduced operating time
5. Bacterial counts are reduced thereby providing a relatively sterile operating field
6. There is little or no postoperative swelling due to sealing of blood vessels and lymphatics

Important principles to remember are the principles guidelines of biopsy and the principles of laser.

Principles of Biopsy Procedure

- Biopsy must be carried out as soon as possible.
- The choice of the biopsy technique is determined by the indications of each

case.

- Avoid inject local anesthetic solution inside the lesion because there is a possibility of causing distortion to the tissues.
- Avoid use of suction devices because you may lose your specimen in the suction.
- Used sharp scalpel to avoid tearing tissues.
- If biopsy performed on mobile tissues (tongue, lip, soft palate, floor of mouth and buccal mucosa) must be stabilized in order to accurate make incision. The methods used to stabilize it are: finger stabilization, retraction suture, towel clips and retractors.
- Avoid using electrosurgical blade due to the resulting high temperature, which causes coagulation and destruction of tissues.
- Avoid grasped with forceps but when their use is necessary, the normal part of the removed tissue should be grasped.
- The tissue specimen taken should be representative.
- Immediately after its removal, the tissue specimen should be placed in a container with fixative. Keeping the tissue specimen outside of the container for a prolonged period dries the specimen, while there is a risk of it falling or being misplaced.
- The fixative solution to be used is 10% formalin or 70% alcohol, and not water or other liquids that destroy the tissues.
- It is recommended that the container to be sent to the laboratory is plastic to avoid risk of breakage during its transfer and subsequent loss of the specimen.
- The label with the name of the patient and date should be placed on the side of the container and not on the lid. This way the possibility of mix-up at the laboratory after opening is avoided.
- The larger the lesion, the more numerous the biopsies that should be taken.
- In ulcerated tumor avoid taken biopsy from the central area (show only necrosis)
- If you want to put land marks on tissue use suture but don't use iodine or highly colored antiseptic.
- A written consent from the patient prior to the biopsy procedure is very

Dr. Afrah Adnan Abdulaim

important, as there are risks involved in biopsy procedures such as paresthesia, and swelling.

- During the biopsy procedure, consideration should be given to anatomical structures like neurovascular bundles that should be handled with care.

Laboratory techniques in histopathology

1-Fixation: Of the many fixatives that have been proposed, 10% buffered formalin remains the best one because it is inexpensive, the tissue can remain in it for prolonged periods without deterioration, and it is compatible with most special stains, including immunohistochemical techniques, as long as the tissue is placed in fixative shortly (<30 min) after surgical removal, and overfixation (>24–48 hours) is avoided. Other fixative solutions are as follows:

- Zenker fluid (which incorporates mercuric chloride) is an excellent fixative, one of the best that has ever been devised for light microscopic work, but it is expensive, requires careful disposal of the mercury.
- Bouin fixative (which contains picric acid) has been especially recommended for testicular biopsies.

Bouin, Zenker, and B-5 are excellent fixatives for routine work and for most immunohistochemical stains, but the preservation of nucleic acids is very poor.

2-Laboratory tissue processing

It refers to any treatment of tissues necessary to impregnate them with a solid medium to facilitate the production of sections for microscopy.
1- Labeling of tissue
2- Completion of fixation process
3- Gentle and complete dehydration to remove aqueous fixative and any tissue watere.g. Ethanol and alcohol
4- Clearing with a substance which is totally miscible with both the dehydrating agent which precedes it and the embedding agent which follows it. e.g. Xylene

5- Embedding e.g. wax, resins and agarwe have two types of tissue processing. Manual and automated tissue processing
6- Microtomy-is the sectioning of tissue blocks by microtome
7- Staining either by ordinary stains (hematoxylin and eosin) or special stains

Special stains

1. Periodic acid–Schiff (PAS) stain. This is an extremely useful and esthetically pleasing technique, and makes evident most types of fungi and parasites.

2. Stains for microorganisms. These include techniques for gram-positive and gram-negative bacteria, acid-fast mycobacteria, fungi, and parasites.

3. Argentaffin and argyrophilic stains. Silver stains are mainly used for the identification of neuroendocrine cells and their tumors, but also for the demonstration of reticulin fibers, melanin, and calcium.

4. Amyloid stains. The mysteriously named Congo red followed by examination with both standard and polarized light (the notorious apple green birefringence) is regarded as the most reliable and practical technique to detect amyloid.

5. Reticulin stains. Reticulin stains demonstrate both 'reticular fibers' and basement membrane material.

6. Trichrome stain. The main value of this group of stains is in the evaluation of the type and amount of extracellular material.

7. Phosphotungstic acid–hematoxylin (PTAH) stain.

8. Stains for hemosiderin (Perls), melanin (Fontana–Masson), and calcium (von Kossa).

9. Stains for neutral lipids.

10. Mucin stains. since it demonstrates mucosubstances of neutral, slightly acidic, and highly acidic types

Dr. Ayad Adnan Alkhalidi

Immunohistochemistry

It is the application of immunologic principles and techniques to demonstrate molecules in cells and tissues. The original method, brilliantly conceived by Coons, consisted of labeling with a fluorescent probe an antibody raised in rabbits and searching for it (and therefore for the antigen against which the antibody was directed) in tissue sections examined under a fluorescent microscope following incubation. The technical improvements that supervened in subsequent years have been responsible for these methods becoming a staple of the histopathology laboratory. The most important diagnostic applications of immunohistochemical marker that have been applied widely to surgical pathology problems, whether as diagnostic aids, prognostic or predictive indicators, or as histogenetic probes are listed as follows:-

- Actin: It is an extremely useful marker for the identification of smooth muscle cells and myofibroblasts
- Albumin: It is an extremely useful marker for the identification of the blood serum proteins. It is potentially a good marker for hepatocellular and hepatoid carcinomas,
- P53. Mutations of the TP53 tumor-suppressor gene represent the most common genetic alteration in human tumors
- S-100 protein. This is a family of acidic, dimeric, calcium-binding proteins. Its main use is in the evaluation of peripheral nerve sheath and melanocytic tumors
- Desmin. This muscle-type intermediate filament (MW 55?000) is found in cells of smooth and striated muscle and in a lesser amount in myofibroblasts. Therefore it has been primarily used for the identification of smooth muscle and skeletal muscle tumors.
- CD34. This marker stains normal and neoplastic endothelial cells, as well as a variety of soft tissue neoplasms, including dermatofibrosarcomaprotuberans, solitary fibrous tumor

Dr. Ahmed Adnan Aldulaimi

Digital pathology and Telepathology

Capture digital images of gross and microscopic specimens which can be integrated with pathology reports.

Telepathology is mean that uses telecommunications technology to facilitate the transfer of image-rich pathology data between distant locations for the purposes of diagnosis, education, and research.

Pathology report:

The usual pathological report is composed of five major fields:

1. Dermographic informations
2. Gross description
3. Microscopic finding
4. Diagnosis
5. Note or comment

Dr. Afrah Adnan Al-Zaidi

References:

- Oral and maxillofacial pathology A Rationale for Diagnosis and Treatment. Robert E. Marx & Diane Stern. Quintessence Publishing Co, Inc; Second Edition;2012.
- Essentials of Oral Medicine. Gautam Srivastava. Jaypee Brothers Medical Publishers; first edition; 2008.